

SKIN GRAFT

87-year old male patient with failure of full thickness skin graft following traumatic wound (fall), lower leg

PREVIOUS TREATMENT

Antibiotic therapy and grafting with full thickness skin. Graft did not take and start treatment with ① 10 days after surgery.

TREATMENT WITH ①

Wound cleansing with saline solution and application of ①. The wound was initially covered with a paraffined gauze, thereafter with a non-woven gauze. Mechanic debridement was performed once per week with a swab.

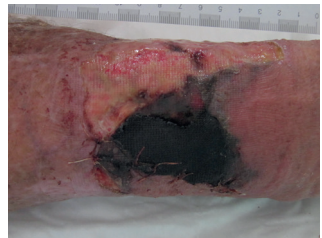RESULT

Wound closure within 14 weeks.

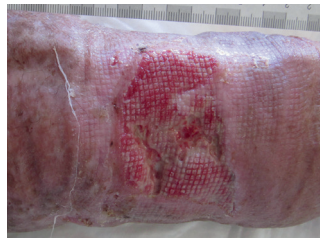
CONCLUSION HEALTH CARE PROFESSIONAL

Dr. M. Palombi, MD, Italy

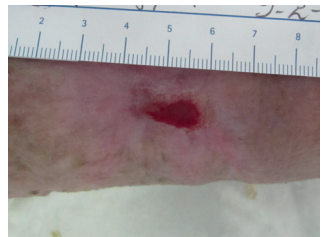
“① enabled a very simple dressing change. Given the patient’s age and the fact that the graft failed to take, it was very impressive to see that the wound was fully covered with healthy granulation tissue in a very short time. The quality of the healed skin was stable, which is particularly important with older patients.”



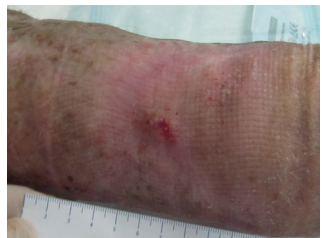Day 0



week 4



week 11



week 14

MANUFACTURER
Phytoceuticals AG
CH-8134 Adliswil

FURTHER INFORMATION
www.wound.ch
Tel. +41 58 800 58 58

