

# PILONIDAL SINUS

20-year old female patient with a pilonidal sinus wound with a wound depth of 4cm and a wound size of 19cm<sup>2</sup>

## PREVIOUS TREATMENT

Surgical excision. Healing of pilonidal sinus wound by secondary intention. Treatment with ① started on day 2 after excision.

## TREATMENT WITH ①

Wound cleansing with water, application of ① and coverage with a non-woven gauze.

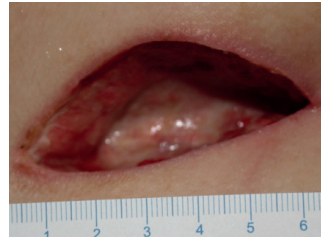
## RESULT

Wound closure within 57 days.

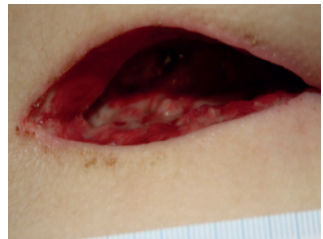## CONCLUSION HEALTH CARE PROFESSIONAL

*Dr. A. Lenz, MD, Switzerland*

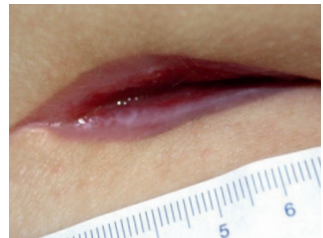“Time to healing for this large wound was 57 days. Compared to standard moist wound treatment in literature this seems to be faster. The fact that the dressing change with ① is very simple is a big advantage for the patient. After having treated more than 30 cases of pilonidal sinus wounds with ①, I conclude that ① offers a clinically efficient and cost-effective therapy for the secondary intention healing of pilonidal sinus wounds following an excision.”



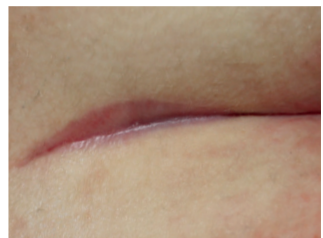Day 1



Day 14



Day 28



Day 57

## MANUFACTURER

Phytoceuticals AG  
CH-8134 Adliswil

## FURTHER INFORMATION

[www.wound.ch](http://www.wound.ch)  
Tel. +41 58 800 58 58

