

# SCALP WOUND

90-year old patient with a scalp wound (with exposed bone) following a tumor excision.

## PREVIOUS TREATMENT

Surgical excision of a tumor. Healing by secondary intention with hydrogel and fatty gauze for 30 days without improvement of the wound condition. Treatment with ① started 30 days following the excision.

## TREATMENT WITH ①

Wound cleansing with water, application of ① and coverage with a plaster.

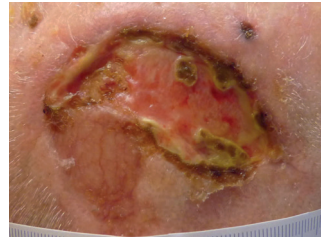
## RESULT

Wound closure within 55 days.

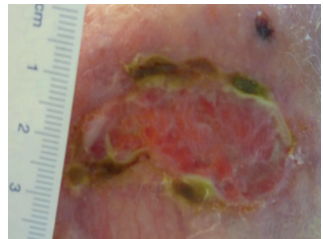
## CONCLUSION HEALTH CARE PROFESSIONAL

*Dr. S. Läuchli, MD, Switzerland*

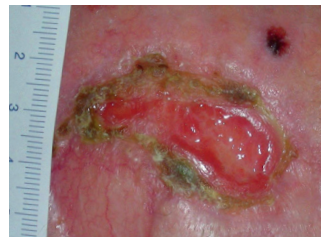“The exposed bone was quickly covered completely with granulation tissue. The patient reported that he did neither experience pain during the dressing change nor between the dressing changes. There have been no clinical signs of infection or an allergic reaction during the entire course of treatment. Treatment of surgical wounds with exposed bone with ① is a promising alternative if compared to primary closure. This is especially true for older multimorbid patients with a high operation risk.”



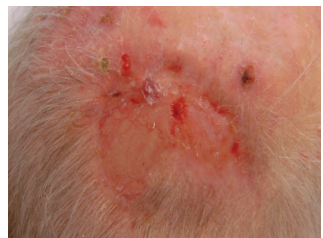Day 1



Day 14



Day 27



Day 55

## MANUFACTURER

Phytoceuticals AG  
CH-8134 Adliswil

## FURTHER INFORMATION

[www.wound.ch](http://www.wound.ch)  
Tel. +41 58 800 58 58

