

# VENOUS LEG ULCER

40-year old male patient with chronic venous insufficiency and a venous leg ulcer on the lower leg following a trauma

## PREVIOUS TREATMENT

Treatment during 6 months with modern wound dressings without improvement. Compression therapy was not performed consistently.

## TREATMENT WITH ①

Wound cleansing with saline solution, application of ① and coverage with a protective wound contact layer and a non-woven gauze. Due to severe pain a protective wound contact layer was used under the non-woven gauze in order to be 100% sure that the gauze did not adhere to the wound. In addition, compression therapy was adjusted and performed consistently.

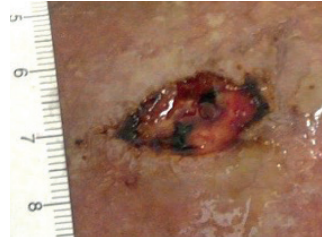
## RESULT

Wound closure within 42 days.

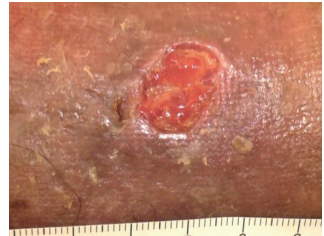
## CONCLUSION HEALTH CARE PROFESSIONAL

Dr. S. Läubli, MD, Switzerland

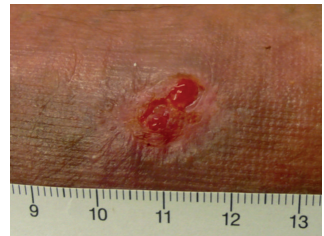“This case shows how important a causal therapy is when treating wounds. The wound healing process stagnated until the compression therapy was performed consistently. The use of ① led to an impressive granulation once the wound had the chance to heal. In addition, ① enabled a very simple and pain-free dressing change. This was particularly helpful for this patient as he was very scared to experience pain during the dressing changes.”



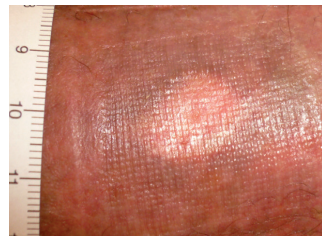
Day 1



Day 8



Day 24



Day 42

## MANUFACTURER

Phytoceuticals AG  
CH-8134 Adliswil

## FURTHER INFORMATION

www.wound.ch  
Tel. +41 58 800 58 58

